

Use of the da Vinci Robot at St Vincent's in Kidney and Head and Neck Cancer

Dr Phillip Brenner
Dr Carlo Yuen

INTRODUCTION

Robotic surgery has enhanced our ability to remove kidney cancer while preserving the rest of the kidney and does so in a minimally invasive fashion.

St Vincent's Private Hospital was the first hospital in NSW to use a 'state-of-the-art' da Vinci SI surgical robot which has further refined this surgery (**Figure 1**).

Part A: Robotic-Assisted Partial Nephrectomy at St Vincent's for Kidney Cancers

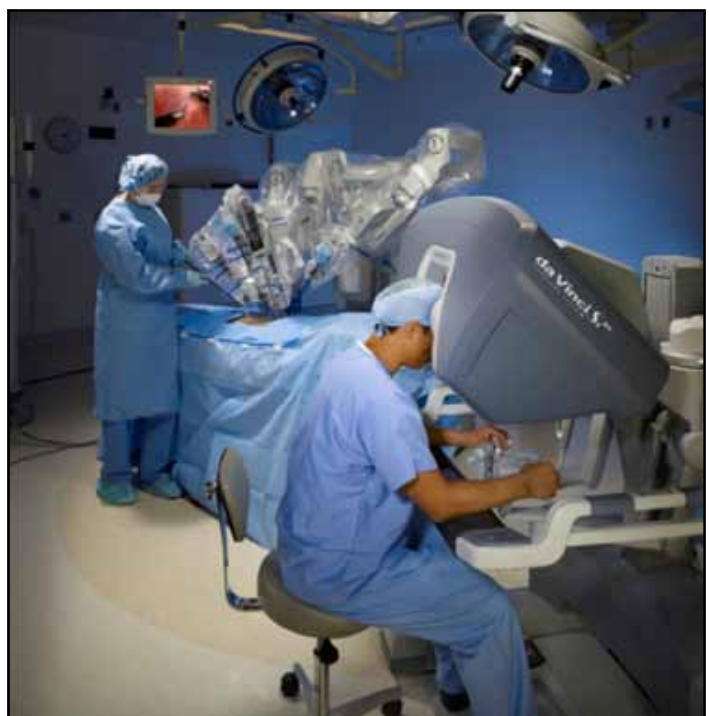

Dr Phillip Brenner



Dr Carlo Yuen

Figure 1. The da Vinci Robotic System



Dr Phillip Brenner, MBBS (UNSW), FRACS (Urology)
Head, Department of Urology, St Vincent's Hospital
Conjoint Senior Lecturer, UNSW.
Fellowship Urological Oncology (Mskcc)

Dr Carlo Yuen, MBBS, FRACS (Urology)
Consultant Urologist
Conjoint Senior Lecturer (UNSW)

RENAL CELL CARCINOMA AND ITS TREATMENT

Renal cell carcinoma is one of the most surgically curable tumours when diagnosed in the early stages. It is relatively resistant to radiation and there is only slight response to some of the new chemotherapeutic agents.

Fortunately, most tumours are diagnosed in the very early stages when found incidentally on ultrasound or computerised tomography (CT) scan being done for other indications. Since the introduction of CT scan and ultrasound, the cure rate for kidney cancer is in excess of 80 per cent and approaches 100 per cent for smaller tumours.

Historically kidney cancer was treated with "radical nephrectomy" ie, removal of the entire kidney through a large incision

between the ribs on the side of the body. Often nerves to the abdominal muscle and skin are cut during this process, leaving a bulging and numb area.

In the early 1990s, laparoscopic radical nephrectomy was perfected allowing a minimally invasive approach to cure kidney cancer.

In recent years, it has become apparent that removal of the tumour alone (sparing the rest of the kidney) for tumours 5cms and less, has the same cancer cure as radical nephrectomy with less risk of kidney disease and/or dialysis at a later stage. This was also originally done through a large incision between the ribs.

Minimally invasive or laparoscopic partial nephrectomy was developed to achieve both sparing of the kidney and a minimally invasive surgical approach. However, the limits of laparoscopy in terms of dexterity, visualisation and control of bleeding limits the effectiveness of this technique.

I performed a large series of these but the procedure was hindered by being technically difficult and slow - especially while repairing the kidney after removal of the tumour. Because the blood supply of the kidney is interrupted during the excision of the tumour and repair of the kidney, the longer the procedure, the greater the risk of potential damage to the kidney due to lack of blood supply.

The development of the da Vinci Robotic system overcame many of these limitations.

DA VINCI ROBOTIC SYSTEM AND ROBOTIC PARTIAL NEPHRECTOMY

The da Vinci Robot gives a highly magnified three-dimensional view of the operative field using two separate cameras, allowing depth perception and facilitating accurate placement of surgical sutures.

The movement of the robotic arms are "scaled down" so a large movement of the surgeon's hands become a much smaller movement of the surgical instrument, allowing more delicate work. Any surgical tremor is eliminated.

The robotic instruments mimic the human wrist and have seven degrees of movement, increasing dexterity when

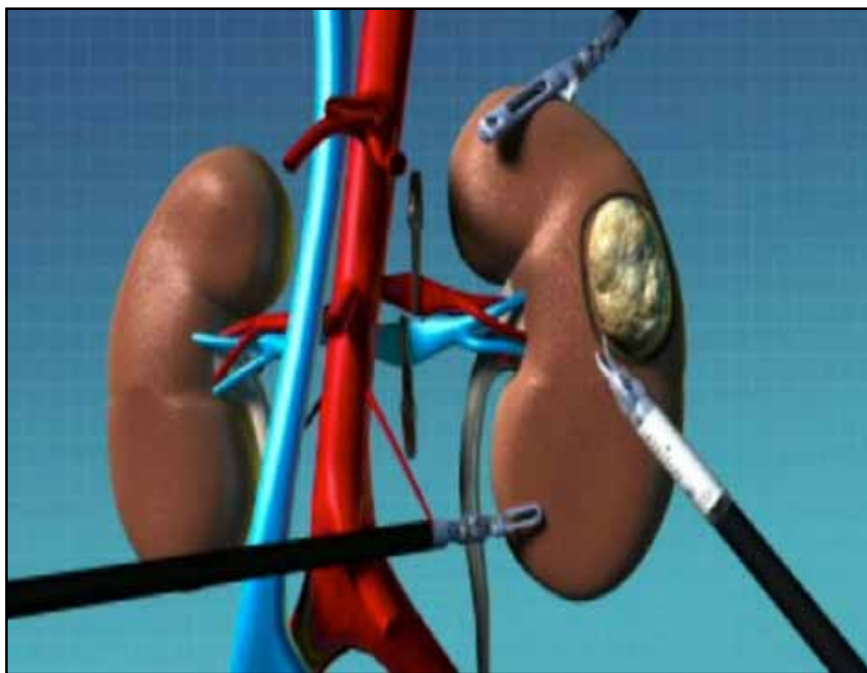


Figure 2
Schematic of tumour of the left kidney. The left renal artery and vein are clamped. The tumour is being excised by the robotic scissors.

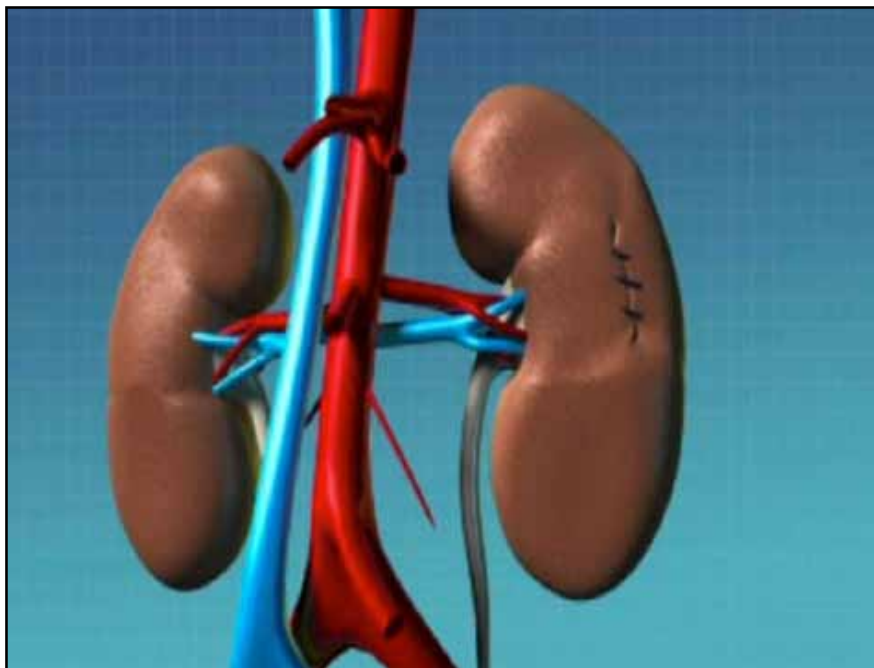


Figure 3
Tumour removed and kidney repaired with sutures.

compared to rigid laparoscopic instruments. This allows more accurate and rapid surgery, minimising the time the kidney is deprived of blood.

Robotic partial nephrectomy is a sophisticated and technically challenging operation, ideally only performed in selected centres. At St Vincent's, the development of da Vinci robotic-assisted laparoscopic partial nephrectomy was personally preceded by experience in over 850 standard laparoscopic kidney procedures and subsequently a series of 20 laparoscopic partial nephrectomies.

At St Vincent's, robotic training was drawn from over 400 robotically-assisted radical prostatectomies since the introduction of the robot.

There are essentially eight surgical steps: five small skin incisions are made to allow the introduction of the laparoscopic instruments; the kidney is freed from the surrounding organs; the artery supplying blood to the kidney and the vein draining blood from the kidney and the ureter are all exposed; the tumour itself is exposed. This is assisted by intra-operative ultrasound which is incorporated in the da Vinci SI by "Tilepro" technology. The tumour is marked by cautery leaving an adequate margin of healthy tissue; the artery and vein are clamped to allow a bloodless dissection with excellent view of the tumour and normal tissue; the tumour is excised sharply (see Figure 2) with scissors to allow appreciation of the tissues so that no tumour is cut through; the defect in the kidney is repaired with sutures to prevent bleeding or urine leakage (see Figure 3). This step is particularly enhanced by the robotic dexterity and view and minimises the time that the kidney is without blood; and the clamp on the renal artery and vein are then removed and blood flow is restored to the kidney.

Post-operatively, patients are expected to be in hospital for two nights. Most will return to work within 1-2 weeks and will return to normal sporting activities in six weeks.

THE ST VINCENT'S ROBOTIC EXPERIENCE

We now offer robotically-assisted laparoscopic partial nephrectomy to

Table: OPERATIVE RESULTS

Patient Number	Tumour Size	Ischaemic Time	Blood Loss
1	14x12x12	20 min 56 sec	Negligible
2	15x15x12	24 min	Negligible
3	40x35x18	16 min	Negligible
4	20x15x22	25 min	Negligible
5	21x16x13	20 min	Negligible
6	24x20x20	16 min	Negligible
7	50x48x45	30 min	Negligible
8	55x55x40	10 min	Negligible
9	40x35x30	12 min 30 sec	Negligible
10	18x15x15	15 min	1000cc
11	28x23x24	8 min	Negligible
12	35x35x24	9 min	Negligible
13	39x49x46	4 min	Negligible
14	20x20x28	16 min	Negligible

suitable patients with small (< 5cm) tumours if the tumour is in a favourable position.

This initial report of the first fourteen (14) patients indicates excellent early results (see Table). Patients had tumour adequately removed with a cuff of normal tissue. In only one patient was tumour found in a small vein at the point of resection – no extra treatment was required. Most patients had blood flow interrupted for less than 20 minutes and none had blood flow interrupted for more than 30 minutes. All but one patient have retained excellent function in the affected kidney. Very few complications have been encountered with one patient developing deep venous thrombosis (having had this after previous surgery as well) and one patient requiring a further laparoscopy to exclude possible complications (no complication was found).

CONCLUSION

Da Vinci robotic-assisted laparoscopic partial nephrectomy should now be regarded as the gold standard for smaller renal tumours, both in terms of cancer control, preservation of kidney function and excellent functional results due to the minimally invasive nature of the surgery.